

## Pneumonia in a patient with lung cancer

### *Pneumonia em paciente com câncer pulmonar*

Vitorino Modesto dos SANTOS<sup>1,2</sup>  
ORCID iD 0000-0002-7033-6074  
Lister Arruda Modesto dos SANTOS<sup>3</sup>  
ORCID iD 0000-0003-4647-4044

#### ABSTRACT

The aim of the present report is to alert health care workers about a 64-year-old patient diagnosed with adenocarcinoma in the right lung treated with pemetrexed disodium, cisplatin and dexamethasone. He evolved with prolonged neutropenia, symptoms of lower airways infection, and recent pulmonary infiltrate in the radiographic image. The cultures for bacteria and mycobacteria in the blood and sputum were negative. Because of the lack of response to treatment with broad spectrum antibiotics and maintenance of neutropenia, a transbronchial biopsy was performed, which demonstrated infection by *Aspergillus fumigatus*. The patient was treated.

**Keywords:** *Aspergillus*. Immunosuppression. Neutropenia. Pulmonary aspergillosis.

#### RESUMO

*O objetivo do presente relato é alertar os profissionais de saúde sobre o caso de um paciente de 64 anos de idade com diagnóstico de adenocarcinoma no pulmão direito tratado com pemetrexede dissódico, cisplatina e dexametasona. Ele evoluiu com neutropenia prolongada, sintomas de infecção de vias aéreas inferiores e infiltrado pulmonar recente na imagem radiográfica. As culturas para bactérias e micobactérias no*

---

<sup>1</sup> Universidade Católica de Brasília, Curso de Medicina. Campus I, QS 07, Lote 1, EPCT, Águas Claras, 71966-700, Brasília, DF, Brasil. *Correspondência para/Correspondence to:* VM SANTOS. E-mail: <vitorinomodesto@gmail.com>.

<sup>2</sup> Hospital das Forças Armadas. Brasília, DF, Brasil.

<sup>3</sup> Hospital dos Servidores do Estado, Departamento de Cirurgia Geral e Oncocirurgia. São Paulo, SP, Brasil.

*sangue e escarro foram negativas. Por falha na resposta ao tratamento com antibióticos de largo espectro e manutenção da neutropenia, foi realizada biópsia transbrônquica que demonstrou infecção por Aspergillus fumigatus e o paciente foi tratado.*

**Palavras-chave:** Aspergillus. Imunossupressão. Neutropenia. Aspergilose pulmonar.

## INTRODUCTION

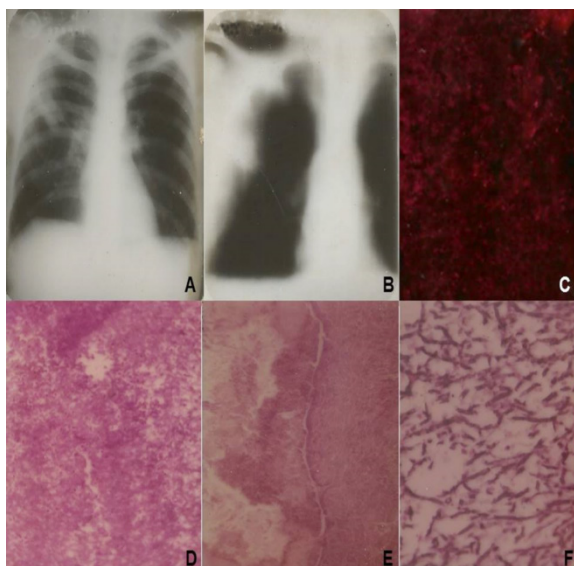
Neutropenia is a peripheral blood Absolute Neutrophil Count (ANC) lower than  $500/\text{mm}^3$ , and may occur in hematologic malignancy and bone marrow or solid organ transplant [1]. Prolonged neutropenia is defined when this change persists for more than 10 days [1]. Invasive Pulmonary Aspergillosis (IPA) usually affects individuals with prolonged neutropenia, which has been considered the major risk factor for this severe infection [1-5]. Corticosteroid therapy plays an additional role in severity and duration of neutropenia [1]. The clinical presentations of this mycosis are allergic bronchopulmonary aspergillosis, chronic necrotizing pulmonary aspergillosis, aspergilloma, and invasive aspergillosis [3]. Indicative data of pulmonary aspergillosis are clinical and imaging findings, elevated C-reactive protein and erythrocyte sedimentation rate, and positive galactomannan test [3]; diagnosis of IPA depends on histopathological findings of hyphae and positive culture [4,5]. We report a case of IPA in a male patient previously treated for lung adenocarcinoma, who had lung infection by *A. fumigatus* related to neutropenia and corticoid therapy.

The case of a 64-year-old man with IPA after treatment for lung cancer is described. The patient was a tobacco smoker (50 pack-years) and an alcohol abuser. The tumor in the superior lobe of the right lung (Figure 1) was incidentally detected by a chest routine radiograph one year before, and the patient underwent chemotherapy cycles with pemetrexed disodium, cisplatin, and dexamethasone. Although the tumor diameter gradually reduced with treatment, he further presented febrile neutropenia and the ANC persisted lower than  $500/\text{mm}^3$  for more than 10 days. Other abnormal blood tests showed anemia, thrombocytopenia, high C-reactive protein and erythrocyte sedimentation rate, hyponatremia,

hyperglycemia, and low albumin. There were symptoms of lower respiratory infection associated with recent pulmonary infiltrates. Blood cultures and urine cultures were negative; Ziehl-Neelsen stains as well as cultures of sputum for bacteria and mycobacteria were negative. The empirical antibiotic schedule then employed was with ceftazidime and amikacin. Because of the absence of clinical improvement with the broad-spectrum antibiotic therapy, and antecedent of prolonged neutropenia, the transbronchial biopsy was performed. The galactomannan serum level was also determined and positive (1.5ng/mL). Samples were studied by hematoxylin-eosin, periodic acid-schiff staining and silver stains (Figure 1), and cultured in Sabouraud dextrose agar medium. The diagnosis of IPA by *A. fumigatus* was confirmed by culture features – blue-green, powdery, and pale yellow on reverse. Therefore, the patient initially underwent intravenous voriconazole (4mg/kg every 12 hours for 21 days), further switched to oral route (200mg twice daily), with a good outcome. He is under close follow-up in specialized outpatient care, and remains symptomless.

## DISCUSSION

A 64-year-old male with antecedent of right lung adenocarcinoma submitted to chemotherapy and corticosteroids had prolonged febrile neutropenia associated with clinical and radiographic features of pneumonia. Although the initial evaluation did not reveal the exact origin of systemic inflammatory response and respective causal agent, the positive galactomannan test was strongly indicative of Infection by *Aspergillus* [1,3,4]. Biopsy samples of lung tissue were sent to histopathology and bacteriologic studies, and the diagnosis of IPA was finally characterized based on the classical criteria



**Figure 1.** Radiographic findings on occasion of the diagnosis of lung cancer at the right upper lobe (A and B); gross appearance of the lung biopsy specimen (C); photomicrographs of lung specimens showing fungal hyphae: hematoxylin and eosin stain in medium-power (D), and periodic acid of schiff stain in low-power (E); and typical features of the hyphae of *Aspergillus* revealed by silver stain in high-power (F).

[1-5]. In accordance with a previous successful outcome, the authors utilized monotherapy with voriconazole to treat the present case of IPA affecting a patient with lung cancer [3]. Abers *et al.* [1] in a recent study found only 108 (33.9%) cases of prolonged neutropenia among 319 patients with IPA; all them were affected by hematologic conditions. The authors emphasized that neutropenia preceded the IPA in less than 50.0% of cases, and prolonged corticosteroid therapy was more prevalent in the absence of neutropenia [1]. Therefore, the lack of prolonged neutropenia should not exclude the possibility of IPA, and physicians must be aware of other risks of IPA in immunosuppressed people [1]. Lung cancer is a very common malignancy and a major cause of death for cancer; worthy of note is the role of pneumonia and sepsis in the outcome of these patients [2]. Cellular and humoral immune dysregulation in this patient population is related to tumor burden and metastases; or radium therapy, chemotherapy and use of corticosteroids

[2]. Avci *et al.* [2] reviewed 119 patients with lung cancer and pneumonia; and 92 of them had lung infections by *Aspergillus fumigatus* (23.9%), *Haemophilus influenza* (14.1%), *Pseudomonas aeruginosa* (13.0%), *Klebsiella pneumoniae* (9.8%), *Acinetobacter baumannii* (9.8%), *Streptococcus pneumoniae* (8.7%), *Staphylococcus aureus* (6.5%), *Escherichia coli* (4.3%), *Staphylococcus epidermidis* (3.2%), *Enterobacter cloacae* (3.2%), and *Proteus mirabilis*, *Moraxella catarrhalis*, and *Moraxella osloensis* (1.1%). The authors focused on the risk of pneumonia by *Aspergillus* in patients with lung cancer, associated with chemotherapy initiation, immunosuppression, and febrile neutropenia [2]. They mostly highlighted the peculiar microbial spectra of pneumonia in lung cancers and the necessity of considering the main microbial agents before empirical therapy [2]. Diagnosis of IPA is characterized by histopathological finding of hyphae and positive culture; clinical data, imaging and positive serology can yield possible diagnosis [4,5]. The culture positivity is up to 50.0% in bronchoalveolar lavage and 5.0% in blood samples, whereas the galactomannan test has the sensitivity of 82.0% and the specificity of 86.0% [4]. False-positive tests can be related to antibiotics (piperacillin, ticarcillin, and amoxicillin), plasma-lyte, and infections by *Histoplasma*, *Penicillium*, *Alternaria*, and *Paecilomyces* [4]. Distinctive features of the *Aspergillus* hyphae include parallel walls, regular septations, dichotomous branching at 45 degrees, and formation of shoal of fish at low magnification [4]. Among more than a hundred species of *Aspergillus*, *A. fumigatus*, *A. niger*, *A. flavus*, and *A. clavatus* have been the most frequent agents described in human infection [5]. The most common presentation of illness in immunocompromised patients is IPA, which may occur in up to 20.0% of individuals undergoing chemotherapy for leukemia [5]. Imaging studies may show nodules, cavitary, or focal infiltrates; the diagnostic tools include transbronchial, transthoracic, and open lung biopsies; the diagnosis is done by detection of the agent in tissues by silver stain or culture [5]. Rodrigues-Pinto *et al.* [5] detect *A.*

*fumigatus* in a paraesophageal lesion of an old man with acute leukemia and febrile neutropenia utilizing the endoscopic ultrasound fine-needle aspiration.

## CONCLUSION

The purpose of the present case study is to enhance the suspicion index of health care workers about pneumonia caused by aspergillosis related to the treatment of lung cancer.

## CONTRIBUTORS

All authors participated in all phases of the research article.

## REFERENCES

1. Abers MS, Ghebremichael MS, Timmons AK, Warren HS, Poznansky MC, Vyas JM. A critical reappraisal of

prolonged neutropenia as a risk factor for invasive pulmonary aspergillosis. *Open Forum Infect Dis.* 2016;3(1):ofw036.

2. Avcı N, Hartavi M, Kaçan T, Bayındır M, Avcı M, Özakın C, *et al.* Retrospective analysis of the microbiological spectrum of pneumonia in Turkish patients with lung cancer. *Contemp Oncol.* 2016;20(1):63-6.
3. Dos Santos VM, da Trindade MC, de Souza DW, de Menezes AI, Oguma PM, Nascimento AL. A 76-year-old man with a right lung adenocarcinoma and invasive aspergillosis. *Mycopathologia.* 2013;176(1-2):113-8.
4. Lanzarin LD, Mariano LC, Macedo MC, Batista MV, Duarte AN Sr. Conidial heads (fruiting bodies) as a hallmark for histopathological diagnosis of angioinvasive aspergillosis. *Autops Case Rep.* 2015;5(4):9-18.
5. Rodrigues-Pinto E, Lopes S, Principe F, Costa J, Macedo G. Pulmonary aspergillosis diagnosed by endoscopic ultrasound fine-needle aspiration. *Endosc Ultrasound.* 2016;5(1):58-60.

Received: November 9, 2016

Final version: May 16, 2017

Approved: June 20, 2017