



SCINTIGRAPHIC ASSESSMENT OF GASTROESOPHAGEAL REFLUX IN WHEEZING BABIES

CINTILOGRAFIA PARA PESQUISA DE REFLUXO GASTRO-ESOFÁGICO EM BEBÊS CHIADORES

Elba Cristina Sá de Camargo ETCHEBEHERE¹

Maria Angela RIBEIRO²

Allan Oliveira SANTOS¹

José Dirceu RIBEIRO³

Celso Darío RAMOS¹

Mariana da Cunha Lopes LIMA¹

Edwaldo Eduardo CAMARGO¹

Antônio CONDINO-NETO³

ABSTRACT

Objective

Evaluate the role of scintigraphy in the assessment of post-prandial gastro-esophageal reflux in wheezing babies.

Methods

Thirteen wheezing babies with post-prandial gastroesophageal reflux (10 males and 3 females; mean age 11 months; mean weight 11.6kg) were studied (Group 1). Patients were treated with 0.2mg/kg of cisapride, 3 times a day during 4 to 8

¹ Serviço de Medicina Nuclear, Departamento de Radiologia, Faculdade de Ciências Médicas, Universidade Estadual de Campinas. Caixa Postal 6142, Cidade Universitária, Barão Geraldo, Campinas, SP, Brasil. Correspondence to/Correspondência para: E.C.S.C. ETCHEBEHERE. E-mail: <elba@mn-d.com>.

² Serviço de Fisioterapia, Departamento de Pediatria, Faculdade de Ciências Médicas, Universidade Estadual de Campinas. Campinas, SP, Brasil.

³ Departamento de Pediatria, Faculdade de Ciências Médicas, Universidade Estadual de Campinas. Campinas, SP, Brasil.

months (average: 6 months). Post-prandial gastroesophageal reflux was diagnosed by medical history, physical examination, and scintigraphy. Twelve wheezing babies with physiologic post-prandial gastroesophageal reflux (6 males and 6 females; mean age 8.7 months; mean weight 10.7kg) were included as a comparative group (Group 2). Patients were submitted to scintigraphies using 18.5 MBq of ^{99m}Tc -sulfur colloid. Post-prandial gastroesophageal reflux episodes were evaluated according to the esophageal regions. The total duration time of post-prandial gastroesophageal reflux episodes was recorded (seconds). Post-prandial gastroesophageal reflux was considered physiologic when the total duration time of post-prandial gastroesophageal reflux episodes was lower than 8 seconds and limited to the distal esophagus. The patients were submitted to two scintigraphies: a baseline scintigraphy, performed before cisapride therapy and a follow-up scintigraphy, performed after cisapride therapy.

Results

There was a statistically significant reduction in the total duration time of post-prandial gastroesophageal reflux episodes in the upper and middle esophageal regions in the follow-up scintigraphy studies compared to baseline scintigraphy. There was also a reduction in the total duration time of post-prandial gastroesophageal reflux episodes in the distal esophageal regions in the follow-up scintigraphy studies when compared to baseline scintigraphy, however, this reduction was not statistically significant. The total duration time of post-prandial gastroesophageal reflux episodes in the distal esophageal region was significantly higher in Group 1 as compared to Group 2.

Conclusion

Scintigraphy is a non-invasive, easy to perform method for determining the reduction of post-prandial gastroesophageal reflux in wheezing babies. This method, due to the low radiation dose, can be performed repeatedly, in order to attain a proper evaluation of post-prandial gastroesophageal reflux.

Indexing terms: wheezing baby syndrome, gastroesophageal reflux, radionuclide imaging.

RESUMO

Objetivo

Avaliar o papel da cintilografia na pesquisa de refluxo gastro-esofágico pós-prandial em bebês chiadores.

Métodos

Treze bebês chiadores com refluxo gastro-esofágico pós-prandial (10 masculinos e 3 femininos; média de idade 11 meses; peso médio 11,6kg) foram estudados (Grupo 1). Os pacientes foram tratados com 0,2mg/kg de cisaprida, 3 vezes por dia, por 4 a 8 meses (média 6 meses). Refluxo gastro-esofágico pós-prandial foi diagnosticado através da história clínica, exame físico e cintilografia. Doze bebês chiadores com refluxo gastro-esofágico pós-prandial fisiológico (6 masculinos, 6 femininos; média de idade 8,7 meses; peso médio 10,7kg) foram incluídos como grupo comparativo (Grupo 2). Pacientes foram submetidos a cintilografias usando 18,5MBq de colóide- ^{99m}Tc . Refluxo gastro-esofágico pós-prandial foi avaliado de acordo com a região do esôfago. O tempo total de episódios de refluxo gastro-esofágico pós-prandial foi determinado (em segundos). O refluxo gastro-esofágico pós-prandial foi considerado fisiológico quando o total duration time of post-prandial gastro-esophageal reflux episodes foi menor que 8 segundos, e restrito ao terço distal do esôfago. Os pacientes foram submetidos a duas cintilografias: uma cintilografia basal, realizada antes da terapia com cisaprida, e uma cintilografia após tratamento com cisaprida.

Resultados

Houve uma redução significativa do total duration time of post-prandial gastro-esophageal reflux episodes nas porções superior e média do esôfago nos estudos de cintilografia, após tratamento, quando comparados com os estudos de cintilografia basal. Houve também uma redução no total duration time of post-prandial gastro-esophageal reflux episodes na região distal do esôfago nos estudos de cintilografia, após tratamento, quando comparados com os estudos de cintilografia basal, porém esta redução não foi significativa. O total duration time of post-prandial gastro-esophageal reflux episodes no terço distal do esôfago foi significativamente maior no Grupo 1 quando comparado ao Grupo 2.

Conclusão

A pesquisa de refluxo gastro-esofágico através da cintilografia é um método de fácil execução, não invasivo e capaz de determinar a redução no refluxo gastro-esofágico pós-prandial em bebês chiadores. Este método, devido à baixa dose de radiação, pode ser repetido diversas vezes para a avaliação adequada do refluxo gastro-esofágico pós-prandial.

Termos de indexação: *síndrome do bebê chiador, refluxo gastroesofágico, cintilografia.*

INTRODUCTION

Nearly 25% of infants present recurrent wheezing. Risk factors for wheezing include bronchospasms, excess secretions and inflammation. Common etiologies are allergies, viral infection, gastroesophageal reflux (GER), foreign bodies and extrinsic compression of the airways¹.

Gastroesophageal reflux may present itself as regurgitation of saliva or food. The term gastroesophageal reflux disease (GERD) covers a wide spectrum of disorders caused by GER. The frequency, topography, and duration of GER episodes indicate the difference between physiological or pathological GER. Characteristics of pathological GER are the increased frequency, intensity and duration of GER episodes, resulting in damage to the esophagus or respiratory tract². Uncontrolled respiratory disease, as well as wheezing, is often caused by frequent disorders of the lower esophageal sphincter². The high prevalence of GER in wheezing babies is not just a casual association. GER may cause or worsen bronchial obstruction due to aspiration, vagal reflex and increased bronchial reactivity.

Esophageal pH monitoring is considered a gold standard method for diagnosing GER³. However, this method is invasive and expensive. Alternatively, GER

can also be investigated by non-invasive and cost-effective diagnostic methods, such as barium swallow study, scintigraphy or ultrasound⁴. The present study evaluates the role of scintigraphy in the assessment of post-prandial GER in wheezing babies

Treatment of GER involves clinical and, less frequently, surgical management, aiming at a reduction of aggressive factors that cause GER, and an increase of protective factors of the esophageal mucosa. Cisapride, a benzamide used for GER treatment, was selected for this study. It causes the release of acetylcholine at post-ganglionic nerve terminals in the gastrointestinal tract, increases contraction of stomach and esophageal muscles, and eventually, increases the tonus of the lower esophageal sphincter, leading to an acceleration of gastric emptying^{5,6}.

METHODS

Patients And Clinical Protocol

The study included 25 patients diagnosed for the wheezing baby syndrome. The clinical criteria for diagnosing the wheezing baby syndrome, consisted of age and frequency of episodes: patients

should be above 3 months old, and have had at least 3 episodes of wheezing, or one continuous episode, for more than 30 days⁷. All patients underwent routine clinical and laboratory tests (hemogram, serum IgA, IgG, IgM and IgE, Mantoux test, and sweat sodium and chloride measurement).

Patients were then investigated for GER by scintigraphy. They were classified in two groups: Group 1 included 13 wheezing babies with pathologic post-prandial GER (10 males and 3 females; mean age 11 months; mean weight 11.6kg). Group 2 included 12 wheezing babies with physiologic post-prandial GER (6 males and 6 females; mean age 8.7 months; mean weight 10.7kg). Physiologic post-prandial GER was diagnosed when the total duration time of GER was lower than 8 seconds and limited to the distal esophagus⁸.

Group 1 patients with pathologic post-prandial GER were treated with 0.2mg/kg of cisapride, 3 times a day during 4 to 8 months (average: 6 months). They were submitted to two scintigraphies. The first scintigraphy, or baseline scintigraphy (BS), was performed before cisapride therapy. The second scintigraphy, or follow-up scintigraphy, was performed up to 48 hours after discontinuation of cisapride therapy. Group 2 patients with physiologic post-prandial GER did not receive cisapride, and were submitted to baseline scintigraphy only.

All patients used inhalation with fenoterol during bronchial obstruction crisis. The use of inhaled bronchodilators occurred only for short periods of time. Exclusion criteria consisted of cisapride contraindication; use of systemic glucocorticoids or bronchodilators; malnutrition; low stature or weight; chronic diseases such as congenital infection, tuberculosis, cystic fibrosis, cardiac disorders, primary or secondary immunodeficiency, genetic disorders, mental retardation; pneumatocele; pleural effusion; acute respiratory insufficiency; pulmonary abscess.

All studies were performed after parental or guardian written consent. The Medical School Ethics Committee approved the protocol in accordance to Brazil's Ministry of Health Resolution 196/96, and to the Helsinki Convention.

SCINTIGRAPHIC STUDY

A new acquisition protocol for assessing post-prandial GER was developed. Patients were required to fast during 4 hours, and then, they were given milk containing 18.5MBq of ^{99m}Tc-sulfur colloid. Patients being in supine position, sequential images of the thorax and upper abdomen were performed with a low-energy all-purpose collimator, every 2 seconds during 15 minutes, making a total of 450 images, thus obtaining a highly sensitive method for detection of post-prandial GER.

Static images of the same regions were performed 4 and 24 hours after the ingestion of the radiopharmaceutical beverage, to evaluate pulmonary aspiration. A radioactive marker was used to locate the sternum notch and xiphoid process, and thus determine the esophagus area. Regions of interest were included in the entire esophagus area, which was then divided into three portions (lower, middle, and upper portions of the esophagus). Time/activity curves of the lower, middle, and upper portions of the esophagus were generated.

Post-prandial GER episodes were evaluated according to location (lower, middle, upper portions of the esophagus) and duration.

The duration time of all the post-prandial GER episodes (TTGER) were summed up for each esophageal region (lower, middle, upper) and the result was expressed in seconds as TTGER. The TTGER in the lower esophagus was expressed as the sum of the post-prandial GER duration times in all three regions (lower, middle and upper regions); the TTGER in the middle esophagus was expressed as the sum of the post-prandial GER times in the lower and middle regions and the TTGER in the upper esophagus was expressed as the sum of the post-prandial GER times only in this portion of the esophagus.

When the TTGER was less than 8 seconds, post-prandial GER was considered as physiologic and supposed to be limited to the distal esophagus.

Comparisons were established by paired or unpaired Student's t-tests, as indicated. Significance level was considered with values lower than 5% ($p < 0.05$).

RESULTS AND DISCUSSION

Group 1 patients presented a significant reduction on TTGER in the upper and middle esophageal regions in the FU studies compared to BS ($p < 0.05$; paired Student's t-test). They also presented a reduction on TTGER in the distal esophageal regions; however, such reduction was not statistically significant ($p > 0.05$, paired Student's t-test) (Figures 1 and 2).

Compared to group 2, group 1 presented a significantly higher TTGER in the distal esophageal regions ($p < 0.05$; Student's t-test), even after cisapride therapy ($p < 0.05$; Student's t-test) (Figure 3).

The static images, performed at 4 and 24 hours, did not show radiotracer accumulation in the lung fields, therefore indicating that none of the patients presented pulmonary aspiration.

This investigation has shown that the TTGER in the different esophageal regions is inversely proportional to the distance to the lower esophageal sphincter (LES) in both studies (BS; FU). This observation has not been clearly understood in terms of the pathogenesis of post-prandial GER, and even studies with pH probe have not been able to explain which is more detrimental to the patients: several

post-prandial GER episodes confined to the lower esophagus or a few GER episodes that reach the upper esophagus.

Cisapride accelerates gastric emptying, thus lowering the probability of post-prandial GER. In this group of patients, FU exams were performed still under the effect of cisapride. Thus, one has to consider that, in addition to the spontaneous maturation of the lower esophageal sphincter (LES), cisapride probably helped to reduce the TTGER, particularly in the upper and middle esophagus. These findings demonstrated a peculiar clinical situation, namely a reduction of post-prandial GER episodes in the upper esophagus, a region where wheezing, even though secondary to aspiration, is more frequent⁹.

Physiologic post-prandial GER, which may occur during two hours after a meal, is a normal phenomenon in infants below the age of 1 year. Scintigraphy is a post-prandial test that can detect both physiological and pathological post-prandial GER, thus helping the health professional to decide on the treatment and choices of medication, without the need for any other diagnostic method. Scintigraphy is not invasive^{10,11}, there is no need for sedation, is well tolerated, and rapidly performed.

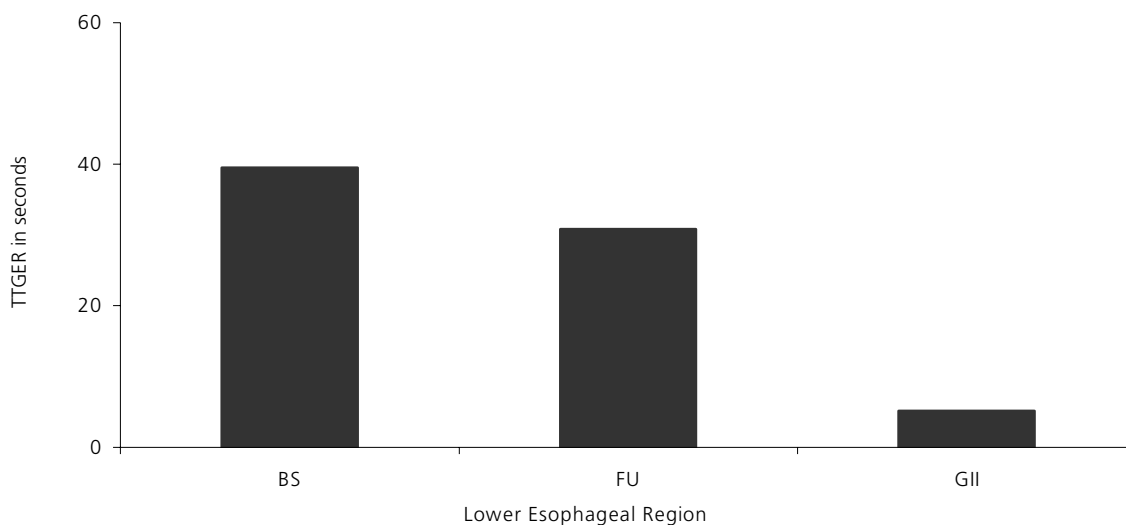


Figure 1. Mean TTGER for each portion of the esophagus in the baseline and follow-up scintigraphy studies.

Note: BS= baseline scintigraphy; FU= follow-up scintigraphy; TTGER= total time of post-prandial gastro-esophageal reflux.

Scintigraphy may also be used for prolonged periods of time without increasing exposure to radiation, consequently being a decisive method of assessing the effect of drugs for GER therapy^{12,13}. Quantification of GER episodes and evaluation of GER characteristics, such as volume and clearance time, can be determined by scintigraphy, as well as pulmonary aspiration can be diagnosed by the same method¹². Latini *et al.*¹³ emphasized that scintigraphy could be considered effective and reliable for

diagnosing post-prandial GER. In this study, post-prandial GER diagnosis was based on history, physical examination and scintigraphy.

Some authors¹³⁻¹⁵ consider scintigraphy better than pH probe monitoring for post-prandial GER diagnosis, while others claim that the opposite is true¹⁶. Vandenplas *et al.*¹⁷ compared scintigraphy with pH monitoring in 65 newborns; they considered both procedures useful in investigating post-prandial GER, even though the two techniques explore differently




Figure 2. (A) BS demonstrating GER. (B) FU of the same patient showing a global reduction of the GER.
 Note: BS= baseline scintigraphy; GER= gastro-esophageal reflux; FU= follow-up scintigraphy.

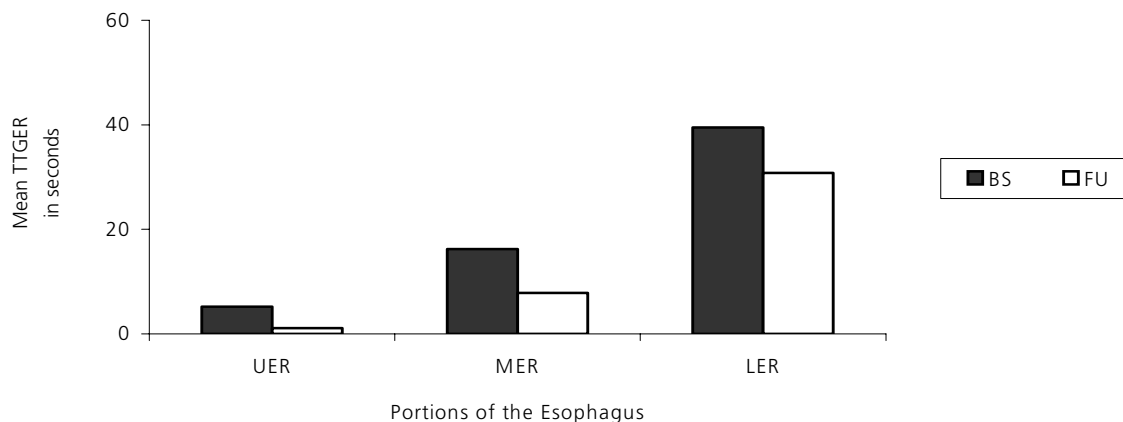


Figure 3. Mean TTGER for the lower esophageal region in the BS and FU studies and in group 2.
 Note: TTGER= total time of post-prandial gastro-esophageal reflux; BS= baseline scintigraphy; FU= follow-up scintigraphy;

the reflux phenomenon differently. The enormous difference between these techniques raises controversies. The above study¹⁷ compared these techniques during the post-prandial period and demonstrated that scintigraphy was more sensitive in detecting post-prandial GER. This can be explained by the fact that the stomach is distended and its pH neutralized by the ingested meal, which means that post-prandial GER is detected by scintigraphy and not by pH monitoring, which is unable to detect neutral GER. Scintigraphy does not depend on the pH of the gastric content to detect post-prandial GER. These authors concluded that pH monitoring, besides being an invasive method, has other disadvantages such as its high cost, the frequently required hospitalization, its indirect measurement of GER, its incapacity to determine the extent of the GER or to detect pulmonary aspiration. Karaman *et al.*¹⁸ evaluated 82 wheezing children and detected GER in 21.9% of them. They concluded that although esophageal pH monitoring has been reported to be the best technique in the evaluation of GER, scintigraphy is very sensitive in the evaluation of children with recurrent wheezing, since it is a non-invasive and easily applicable method.

Ultrasound is a new method for detection of GER episodes, which measures the opening of the LES. However, the method is not quantitative, it cannot determine the extent of the GER episodes in the esophagus, and is not able to detect pulmonary aspiration¹⁹. Some authors propose a combination of diagnostic modalities to diagnose GER in young children²⁰.

The wheezing baby syndrome and GERD continue to draw a great deal of interest, as there are factors that still have to be clarified. The cause and effect relationship between these conditions is still a controversial topic, and the mechanisms involved have to be identified.

Scintigraphy is a non-invasive and sensitive method for detecting post-prandial GER episodes. The acquisition protocol performed in this study, with a total of 450 images, is a highly sensitive and fast method for detection of post-prandial GER, a major

advantage when studying children. Due to its low radiation dose, scintigraphy can be performed repeatedly in wheezing babies. We conclude that this modified scintigraphy protocol was effective for assessing post-prandial GER, making it a suitable protocol for diagnostic and research purposes, regarding gastric motility or lower esophageal sphincter physiology.

A C K N O W L E D G E M E N T S

The authors thank Janssen-Cilag of Brazil for donating Cizapride.

R E F E R E N C E S

1. Martinez FD, Wright AL, Taussig LM, Holdeberg CJ, Halonen M, Morgan WJ, et al. Asthma and wheezing in the six years of life. *N Engl J Med.* 1995; 332(3):133-8.
2. Vandenplas Y, Ashkenazi A, Belli D, Boige N, Bouquet J, Cadranet S, et al. A proposition for the diagnosis and treatment of gastroesophageal reflux disease in children: a report from a working group on gastroesophageal reflux disease. *Eur J Pediatr.* 1993; 152(9):704-11.
3. Hegar B, Vandemaele K, Arana A, Vandenplas Y. Oesophageal pH monitoring in infants: Elimination of gastric buffering does not modify reflux index. *J Gastroenterol Hepatol.* 2000; 15(8):902-5.
4. Meyers W, Roberts CC, Johnson DG, Herbst JJ. Value of tests for evaluation of gastroesophageal reflux in children. *J Pediatr Surg.* 1985; 20(5):515-20.
5. Vandenplas Y, Deneyer M. Gastroesophageal reflux incidence and respiratory dysfunction during sleep in infants: Treatment with cisapride. *J Pediatr Gastroenterol Nutr.* 1989; 8(1):31-6.
6. Bohets H, Lavrijsen K, Hendrickx J, van Houdt J, van Genechten V, Verboven P, et al. Identification of the cytochrome P450 enzymes involved in the metabolism of cisapride: *In vitro* studies of potential co-medication interactions. *Br J Pharmacol.* 2000; 129(8):1655-67.
7. Rozov T, Bresolin AMB. A síndrome do lactente chiador. In: Sampaio MMSC, Grumach AS. *Alergia e imunologia em pediatria.* São Paulo: Sarvier; 1992. p.51-9.
8. Habibian RM, Tedeschi AA. Imaging of the gastrointestinal tract. In: Sandler MP, Patton JA, Shaff MI, Powers TA, Partain CL. *Correlative Imaging.*

- Nuclear medicine, magnetic resonance, computed tomography, ultrasound. Baltimore: Williams & Wilkins; 1992. p.445-80.
9. Brown P. Medical management of gastroesophageal reflux. *Curr Opin Pediatr.* 2000; 12(3):247-50.
 10. Fisher RS, Malmud LS, Roberts GS, Milmoie, G. Gastroesophageal scintiscanning to detect and quantify gastroesophageal reflux. *Gastroenterology.* 1976; 70(3):301-8.
 11. Seibert JJ, Byrne WJ, Euler AR, Latture T, Leach M. Gastroesophageal reflux: the acid test, scintigraphy or pH probe? *Am J Roentgenol.* 1983; 141(1): 1087-90.
 12. Tolia V, Kuhns LR, Kauffman RE. Comparison of simultaneous esophageal pH monitoring and scintigraphy in infants with gastroesophageal reflux. *Am J Gastroenterol.* 1993; 88(5):661-4.
 13. Latini G, Del Vecchio A, De Mitri B, Giannuzzi R, Presta G, Quartulli L, et al. Scintigraphic evaluation of gastroesophageal reflux in newborn. *Pediatr Med Chir.* 1999; 21(3):115-7.
 14. Orenstein SR, Klein HA. Scintigraphy versus pH probe for quantification of pediatric gastroesophageal reflux: A study using concurrent multiplexed data and acid feeding. *J Nucl Med.* 1993; 34(8):1228-34.
 15. McVeagh P, Howman-Giles R, Kemp A. Pulmonary aspiration studied by radionuclide milk scanning and barium swallow roentgenography. *Am J Dis Child.* 1987; 141(8):917-21.
 16. Swischuk LE, Fawcett HD, Hayden CK Jr, Isenberg JN. Gastroesophageal reflux: How much imaging is required? *Radiographics.* 1988; 8(6):1137-45.
 17. Vandenplas Y, Derde MP, Piepsz A. Evaluation of reflux episodes during simultaneous esophageal pH monitoring and gastroesophageal reflux scintigraphy in children. *J Pediatr Gastroenterol Nutr.* 1992; 14(3):256-60.
 18. Karaman O, Uzuner N, Degirmenci B, Uguz A, Durak H. Results of the gastroesophageal reflux assessment in wheezy children. *Indian J Pediatr.* 1999; 66(3): 351-5.
 19. Le Dosseur P, Moutounet L, Eurin D, Monroc M, Dacher JN. Ultrasonography of the esophagus in children. *Ann Radiol.* 1994; 37(7-8):494-9.
 20. Patwari AK, Bajaj P, Kashyp R, Anand VK, Gangil A, Jain A, et al. Diagnostic modalities for gastroesophageal reflux. *Indian J Pediatr.* 2002; 69(2):133-6.

Recebido para publicação em 18 de fevereiro de 2003 e aceito em 14 de outubro de 2004.